

Surgical Technique



Centreline[™] TDR

C O N T E N T S

INTRODUCTION	1
I. PATIENT SELECTION	
Indications	2
Pre-Operative Planning	2
II. ACCESS	
Patient Positioning	3
Surgical Approach	3-5
III. COMPLETE DISCECTOMY	
Discectomy	6
Endplate Preparation	7
IV. IMPLANTATION	
Trialing	8-9
Midline Identification	9-10
Endplate Insertion	11
Core Trial and Insertion	12-13
Final Positioning	14-15

INTRODUCTION

The CHARITÉ™ Artificial Disc is a breakthrough in spinal motion preservation technology for the treatment of degenerative disc disease. The CHARITÉ is comprised of proven orthopaedic materials; cobalt chromium endplates and an Ultra-High Molecular Weight Polyethylene (UHMWPE) sliding core.


CHARITÉ's unique mobile bearing core allows the surgeon to recreate a near-normal axis of rotation, enabling independent translation & rotation, thus reproducing natural spinal motion. Similar to the nucleus of a natural disc, the mobile core moves dorsally during flexion and ventrally during extension.

The CHARITÉ Artificial Disc System includes an extensive range of core heights, endplate sizes and endplate angles providing the surgeon with numerous options to help ensure proper sizing, placement, and segmental lordosis. The CENTRELINE™ Instrumentation aids in midline placement for optimal performance. This comprehensive system is designed to:

- Preserve near normal physiologic motion of the operative spinal segment which may reduce adjacent level degeneration.
- Maintain segmental stability.
- Restore proper disc height.
- Re-establish lordotic alignment.
- Reduce discogenic pain.

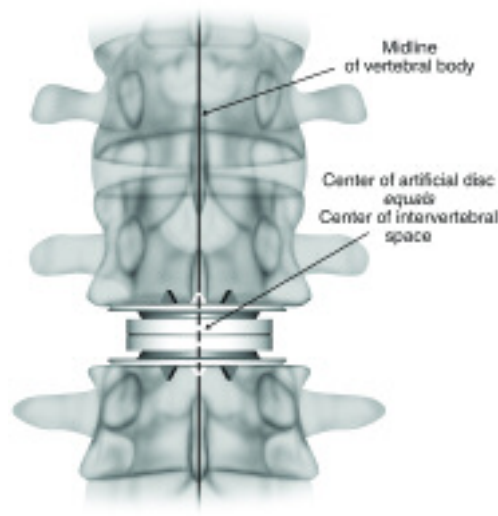
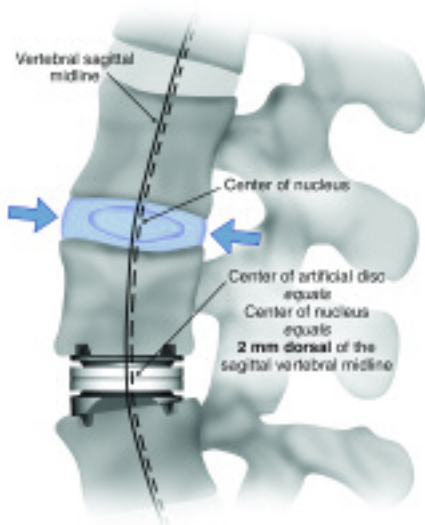But, the successful treatment of degenerative lumbar disc disease does not depend solely on the CHARITÉ Artificial Disc. Other important considerations include:

- Completion of a company-sponsored training program on use of the CHARITÉ Artificial Disc and CENTRELINE instruments.
- Proper patient selection.
- Safe and adequate surgical approach and exposure to the appropriate degenerative disc level.
- Complete discectomy and meticulous endplate preparation.
- Optimal implant size, height and lordosis selection and proper placement.



“Keys to successful placement include strict adherence to the technique that is don't skip steps. If properly done, the Charite Artificial Disc can mimic the function of the natural disc providing the best opportunity for maximum relief of pain.”

Scott Blumenthal, M.D.



CHARITÉ ARTIFICIAL DISC I. PATIENT SELECTION

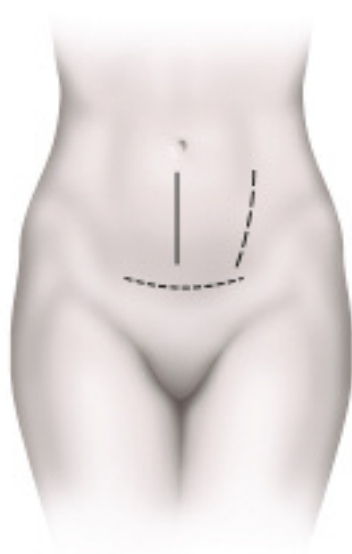
INDICATIONS FOR USE

- The CHARITÉ Artificial Disc is indicated for spinal arthroplasty in skeletally mature patients with degenerative disc disease (DDD) at one level from L4-S1.
- DDD is defined as discogenic back pain with degeneration of the disc confirmed by patient history and radiographic studies.
- Patients receiving the CHARITÉ Artificial Disc should have had at least six months of conservative treatment prior to implantation of the CHARITÉ Artificial Disc. Other prior surgical interventions may include: discectomy, laminotomy/laminectomy (without complete facetectomy), or nucleolysis at the same level to be treated.

PRE-OPERATIVE PLANNING

Successful clinical outcomes with the CHARITÉ Artificial Disc begin with a thorough pre-operative plan. Prior to performing any artificial disc surgery, the following steps are recommended:

- Perform a thorough review of pre-operative patient x-rays to identify any possible contraindications to disc replacement, as well as to gain a pre-operative estimate of the implant size and angle. Pre-operative evaluation of the patient's history, symptoms and radiological studies need to verify that the suspect lumbar disc is the significant pain generator. Often discograms or diagnostic blocks are necessary to verify the site(s) of pain generation.
- Coordinate with a vascular or general surgeon trained as a spinal access surgeon.
- The patient must be placed on a radiolucent operating table that will allow for C-arm movement. Intra-operative adjustability of lordosis using a hinged table or inflatable pillow is often useful during the implant placement.



Skin Incision Options:

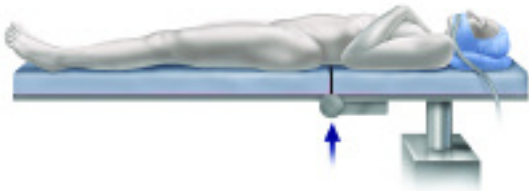
L4-S1
L4-S1
L5-S1

Left retroperitoneal approach is preferred.
4-6 cm incision is recommended for one level.

“Patient selection is the most important part of the entire procedure...I find that a pre-operative visit with the access surgeon is useful for reviewing the history of prior abdominal surgery and selecting the incision.”

Fred Geisler, M.D.

II. A C C E S S

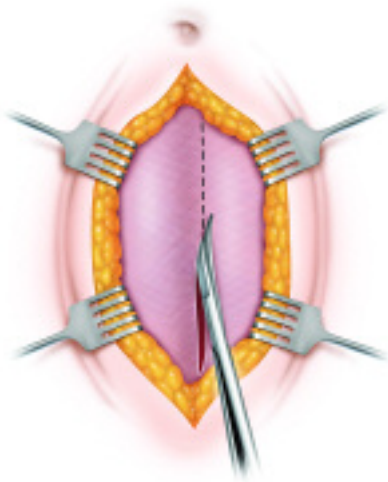


“Good fluoroscopic visualization and the ability to hyperextend the OR table for both discectomy & implantation are critical to successful placement.”

Scott Blumenthal, M.D.

PATIENT POSITIONING

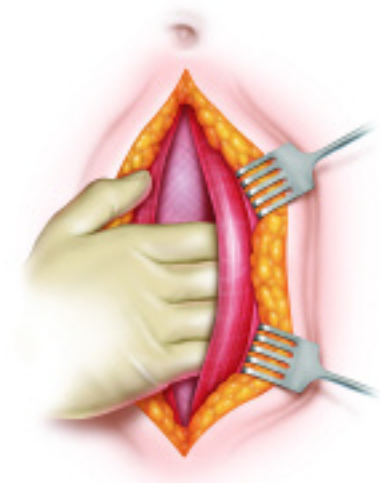
- Place the patient in a supine position on a folding table or over an inflatable pillow.
- Align the break in the table or the inflatable pillow directly under the affected disc.
- The disc space can now be opened by breaking the table (or inflating the pillow) to extend/increase lordosis of the spine or closed by flattening the table (or deflating the pillow) to flex/decrease lordosis of the spine.
- Position the patient’s upper limbs so that there is space for circumferential C-arm movement over and around the operative level.



SURGICAL APPROACH

(Left Paramedian Incision shown)

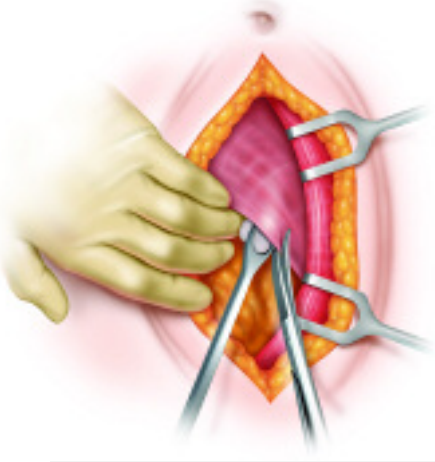
- Make a left paramedian skin incision.
- Retract the underlying subcutaneous tissue until the fascia is exposed. Divide longitudinally with dissecting scissors.



- Retract the left rectus muscle to the left with fingers or blunt retractors.

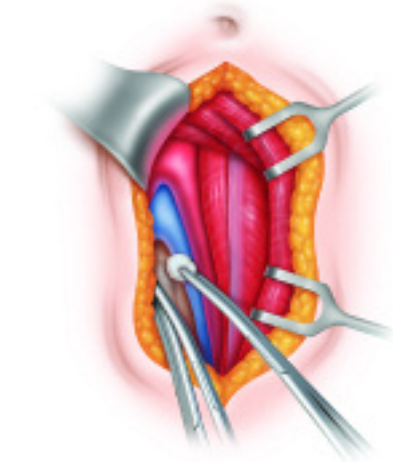
CHARITÉ ARTIFICIAL DISC

II. ACCESS

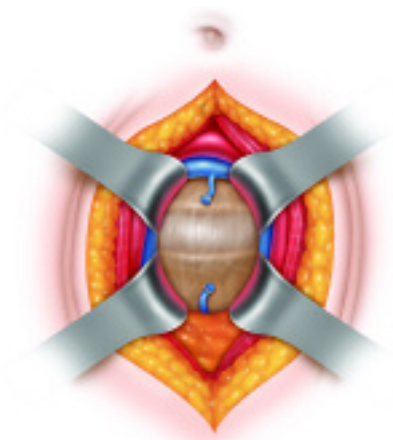


SURGICAL APPROACH

- Raise the underlying fascia. Divide longitudinally with dissection scissors or blunt dissection.

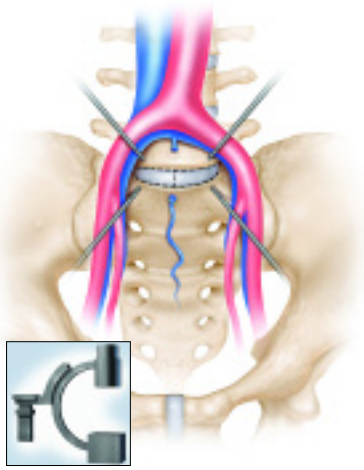


- Identify the psoas, iliac artery, and iliac vein.



APPROACH OF L5/S1

- Expose the L5/S1 intervertebral disc and ligate the median sacral vessels.
- The further dissection of the tissue anterior to the intervertebral disc is mainly by blunt dissection. **Careful attention to dissection and avoidance of electrocautery is advised.** This dissection is carried first to the left and then to the right to achieve the maximum possible lateral exposure of the disc.
- **Extreme care should be taken to protect the left and right common iliac vessels.**
- Bluntly mobilize the left common iliac vein and artery with small swabs and then the right common iliac artery together with the right common iliac vein that lies posterior.
- All of these vessels are retracted laterally and occasionally slightly superiorly.

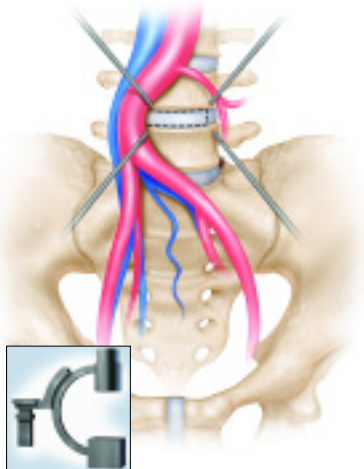


Fluoroscopy

- Carefully impact four Retractor Pins into the adjacent vertebral bodies, or use an appropriate external soft tissue retractor system.
- Verify the vertebral level by lateral fluoroscopy.
- Utilize a midline incision to open the anterior annulus. The flaps may be used for protection of eccentric vessels.

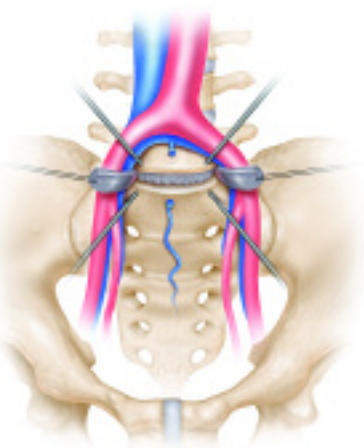
“Be aware that table mounted retractors will cause the patient to roll to the left-hand side.”

Fred Geisler, M.D.



APPROACH OF L4/L5

- Mobilize the iliac vein and iliac artery to the right. Carefully impact four Retractor Pins into the adjacent vertebral bodies, or use an appropriate external soft tissue retractor system.
- Verify the vertebral level by lateral fluoroscopy.
- Utilize a leftward incision to open the anterior annulus. The flap may be used for protection of eccentric vessels.



If desired, hold the annulus fibrosus in position with a suture and mosquito clamp.

CHARITÉ ARTIFICIAL DISC

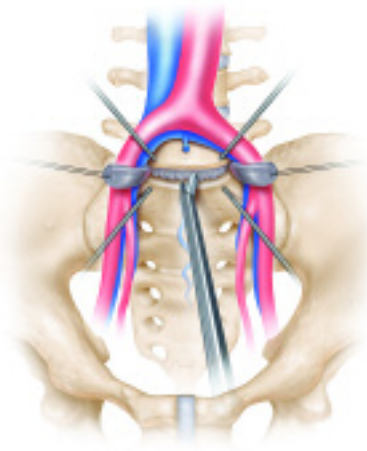
III. COMPLETE DISCECTOMY

TIP: IMPORTANCE OF COMPLETE DISCECTOMY

Performing a complete discectomy is critical to achieving a successful surgery.

Complete discectomy, including the removal of the posterior lateral recesses of the disc facilitates:

- **parallel distraction** which allows for the restoration of intervertebral height & sufficient opening of the neuroforamen,
- **parallel alignment of the inner surfaces of the endplates**, which provides uniform loading of the UHMWPE sliding core allowing near-normal physiologic motion, and
- **sufficient space for the optimally sized CHARITÉ Artificial Disc.**



“Radical discectomy of a magnitude that most surgeons are not used to is critical.”

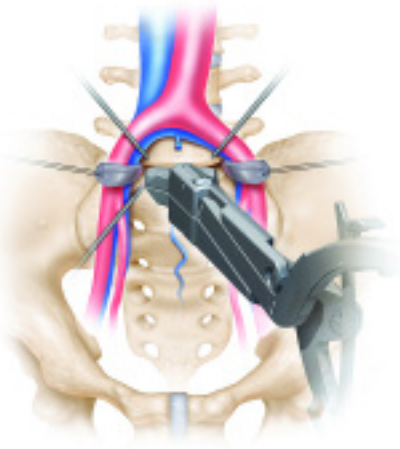
Scott Blumenthal, M.D.

COMPLETE DISCECTOMY

- Perform the initial central discectomy using Rongeurs, Curettes and/or the Disc Elevator.
- **Care must be taken not to damage the bony endplate. See Importance of Endplate Preparation.**

“I make a cautery mark at my initial estimate of coronal midline. Later, the trials are used to accurately identify both midlines.”

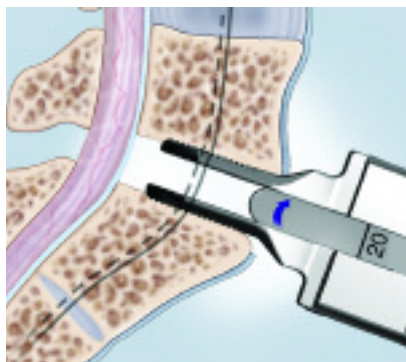
John J. Regan, M.D.



- Apply controlled distraction to visualize and remove the remaining disc tissue, leaving only the lateral annulus using the Spreading and Insertion Forceps.

- **It is imperative to remove the posterior lateral recesses of the disc and to release the posterior annulus. See Importance of Complete Discectomy.**

- Sequentially distract the disc space utilizing the Spacers and Modular T-handle through the spreading tips. **Parallel distraction is critical for restoration of disc height and sufficient opening of the neuroforamen.**



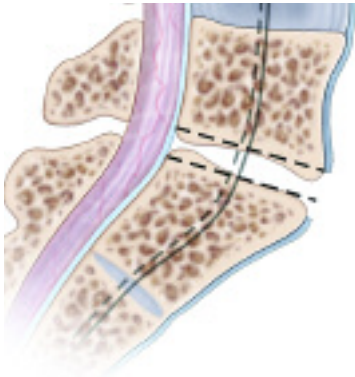
Offset tips aid in entry. If necessary, the guided impactor and/or slap hammer can be added to aid in insertion or removal.

“Make certain the entire anterior aspect of the disc is exposed, for complete discectomy.”

Richard Guyer, M.D.

“It is important to use the Spreading and Insertion Forceps appropriately to avoid over distraction.”

John J. Regan, M.D.



ENDPLATE PREPARATION

- Remove the cartilaginous endplate with the Curettes utilizing a side-to-side motion.
- **Care must be taken not to damage the bony endplate. See Importance of Endplate Preparation.**
- When necessary, carefully shape curved vertebral surfaces by removing dorsal and ventral osteophytes, utilizing the Curettes and Rongeurs, or other appropriate instruments to ensure optimal placement of the CHARITÉ Artificial Disc.

“Unlike a fusion where damaging the endplates is part of the procedure, care must be taken not to damage the endplates.”

Fred Geisler, M.D.

“For epidural or bone bleeding, I find it useful to utilize strips of collagen hemostat approx. 3” long. Lay about three in the blood. Using a standard 4x4 push into the disc space and impact against the PLL. Leave in place for approx. 3 mins to obtain reliable hemostasis.”

Fred Geisler, M.D.

TIP: IMPORTANCE OF ENDPLATE PREPARATION

Preservation of the integrity of the cortical endplate of the intervertebral body is imperative. The preserved endplate:

- ***provides a firm base for mechanical stability, and,***
- ***reduces the potential for subsidence.***

CHARITÉ ARTIFICIAL DISC

IV. I M P L A N T A T I O N

TIP: TRIALING

The Trials mimic the footprint and angulation of the Endplates. Correct sizing, placement and lordotic angle of the CHARITÉ Artificial Disc are critical to ensure optimal performance.

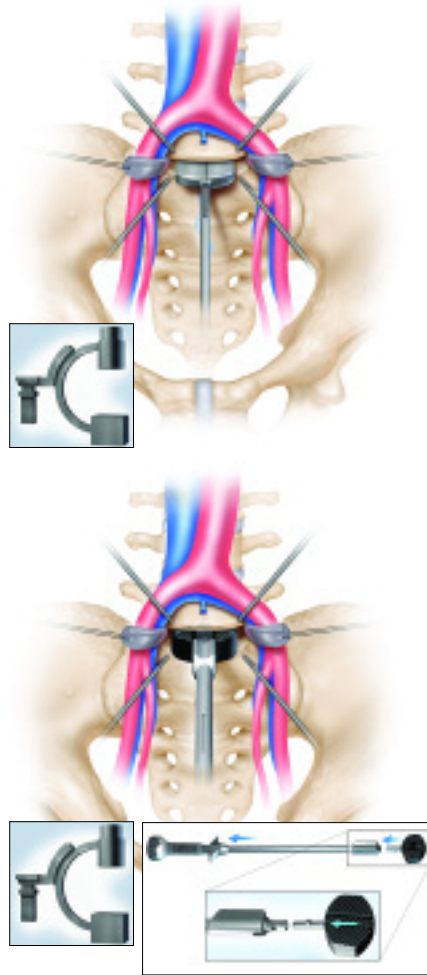
- Choose a Trial footprint that maximizes the area of vertebral endplate that is covered.

- Confirm the ability to place the Trial as follows:

Lateral: center of disc = 2 mm dorsal to midline

AP: center of disc = center of disc space.

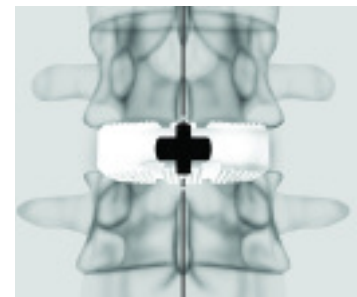
- Choose a lordotic angle that restores the desired segmental lordosis. Always place the larger lordotic angle inferiorly to reduce shear forces and to help protect the prosthesis and posterior elements. The correct angles have been selected if there is no white line visible between the Spreading Tips and the vertebral body.



TRIAL

- If necessary, determine the correct footprint size using the Sizing Gauges which correspond to endplate footprints. Verify correct size by lateral fluoroscopy.
- Select and insert the loaded Trial Insertion Instrument into the disc space **placing the marker side superior. Proper size, placement and lordotic angulation are imperative. See Trialing.**
- Verify the correct footprint size, placement and lordotic angle by AP and lateral fluoroscopy. If necessary, release the Trial from the Trial Insertion Instrument. Adjust the size, positioning or lordotic angle as needed.

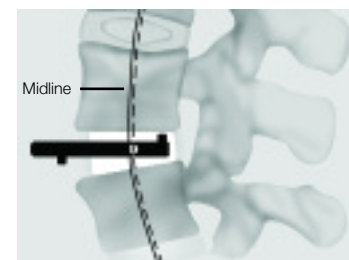
Center of the CHARITÉ Artificial Disc =
Center of the Intervertebral Disc Space



“When choosing endplate size, complete containment of the fixation teeth takes precedence over lateral endplate coverage.”

Richard Guyer, M.D.

Center of the CHARITÉ Artificial Disc =
Center of the Nucleus




“For L5/S1, the L5 endplate is smaller than the S1 endplate. Selection of the endplate size should be based on the L5 endplate.”

Fred Geisler, M.D.

2 mm dorsal to the lateral midline

TRIAL

- For a collapsed disc space, insert the Trial Insertion Guide into the disc space, **placing the marker side superior**. Insert the loaded Trial Insertion Instrument through the Insertion Guide, to distract and place the Trial. Remove the Trial Insertion Guide from the disc space leaving only the Trial.




“One of the most crucial steps is establishing the midline. Check x-rays in the AP to make certain they are aligned similar as the pre-op AP. With the AP image make certain the spinous processes are lined up in the center of the x-ray (i.e. from the 12 o’clock to 6 o’clock position to eliminate parallax and to ensure accurate placement.)”

Richard Guyer, M.D.

MIDLINE IDENTIFICATION

- Once the correct placement of the Trial is verified, insert the Midline Marker into the AP midline of the superior vertebral body placing the loaded Marker Inserter into the grooves on the Trial Insertion Instrument.
- The Midline Marker aids in the correct placement of the instruments and CHARITÉ Artificial Disc.
- Remove the Trial Insertion Instrument.



If necessary, a Slap Hammer can be added to aid in removal.

TIP: MIDLINE IDENTIFICATION

Proper midline identification is critical to the success of any artificial disc procedure. The prosthesis must be placed accurately in both the AP and lateral planes in order to place the CHARITÉ Artificial Disc, and thereby the center of rotation, in the physiologically optimal location.

Achieving a good AP film to define the midline of the vertebral body is critical to proper placement of the device. Positioning the fluoroscopic x-ray machine at the correct angle and position to get a good AP film can be challenging but worth the effort in time and patient outcome. Positioning fluoro so that the pedicles are of equal size and magnification and equidistant from the spinous process are good tips to help aid in placement of the Midline Marker described below.

CHARITÉ ARTIFICIAL DISC

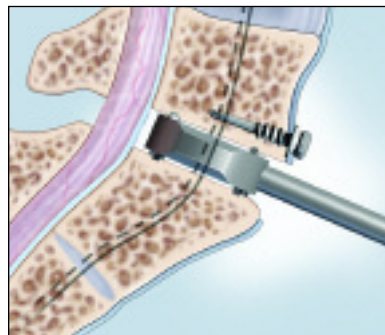
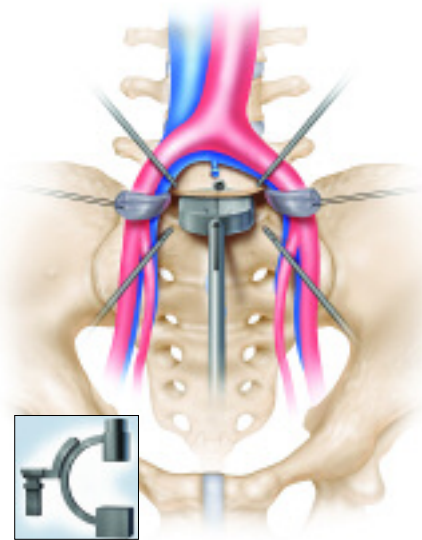
IV. I M P L A N T A T I O N

TIP: CONFIRMING POSITIONING

The use of the Pilot Driver is the last, but most important templating step. The Pilot Drivers match the footprint geometry and closely approximate the height of the two Endplates during implantation.

Thus, if the Pilot Driver can be impacted to the desired location for the prosthesis, successful implantation of the Endplates to that same location can be achieved.

If this is not possible, additional discectomy or endplate preparation will be required.



“The Pilot Driver is necessary to distract the intervertebral space enough to permit the implant to seat properly.”

John J. Regan, M.D.



CONFIRM POSITIONING

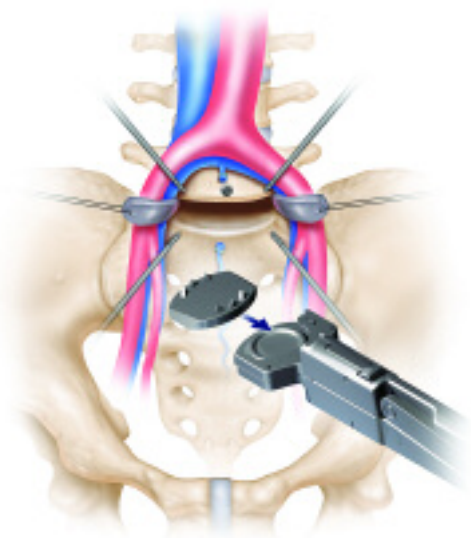
- It is critical to have shaped any curved vertebral surfaces prior to Pilot Driver impaction to reduce the potential for vertebral body or endplate fracture during Pilot Driver impaction.

See Importance of Endplate Preparation on page 7.

- Accurately align the Pilot Driver with the Midline Marker. Carefully impact the Pilot Driver that corresponds to the chosen footprint to verify the ability to accurately place the Endplates into the proper position. The center of the CHARITÉ Artificial Disc should be 2mm dorsal of the lateral midline.
- It may be necessary to increase lordosis in the operative segment to initiate impaction.
- It is important to use lateral fluoroscopy to accurately monitor the depth of the Pilot Driver.
- Place the patient in the neutral supine position when the Pilot Driver is halfway into position.

If necessary the Slap Hammer can be fixed to the Pilot Driver for easy removal from the disc space.

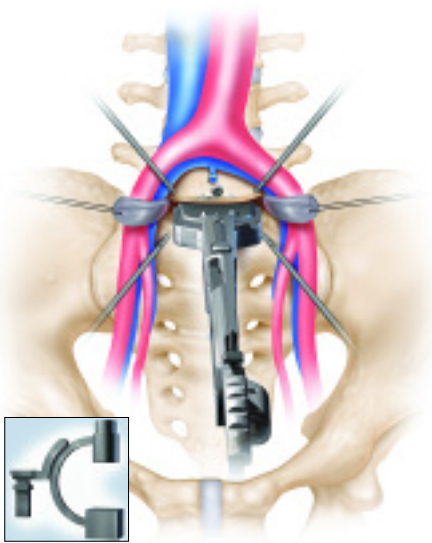
ENDPLATE INSERTION



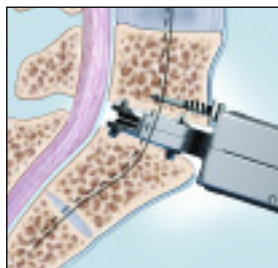
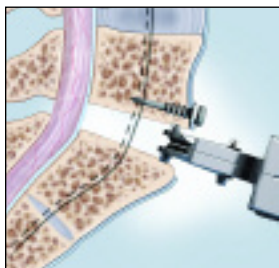
- Attach the Endplate Insertion Tips corresponding to the chosen Endplates size to be used to the Spreading and Insertion Forceps.
- Load the selected Endplates into the Endplate Insertion Tips placing the more angled of the two Endplates inferiorly.
- **When utilizing an Oblique Endplate, load the thicker margin into the Endplate Insertion Tip first. The thick margin must be placed ventrally within the vertebral disc space.**

“When inserting the prosthesis, check the AP view in “reverse” Ferguson to identify that the center fixation tooth is lined with the center before final insertion. ”

Richard Guyer, M.D.



- Carefully position the Spreading and Insertion Forceps paying particular regard to the AP midline.
- Carefully insert the Endplates into the disc space with the assistance of the Guided Impactor.
- Monitor the insertion with fluoroscopy to accurately control the posterior depth, and to verify the appropriate lordotic angle.
- If needed, increase lordosis to initiate impaction of the implant. Bring the table to neutral supine position when the implant is halfway in the disc space.
- The final position of the center of the Endplates should be 2 mm dorsal to the lateral midline of the vertebral body and centered on the medial/lateral midline.

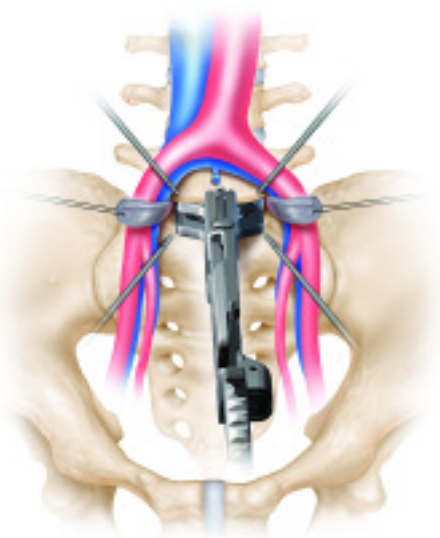


“Continuous c-arm monitoring is done during final implant positioning so that the center of the implant is placed 2-3 mm posterior to the midline of the vertebral body which is close to the center of rotation.”

John J. Regan, M.D.

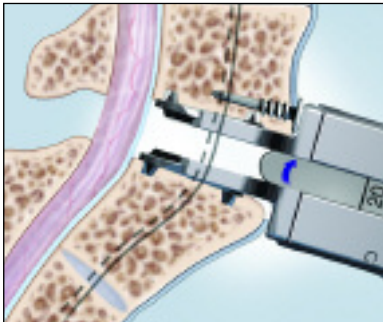
CHARITÉ ARTIFICIAL DISC

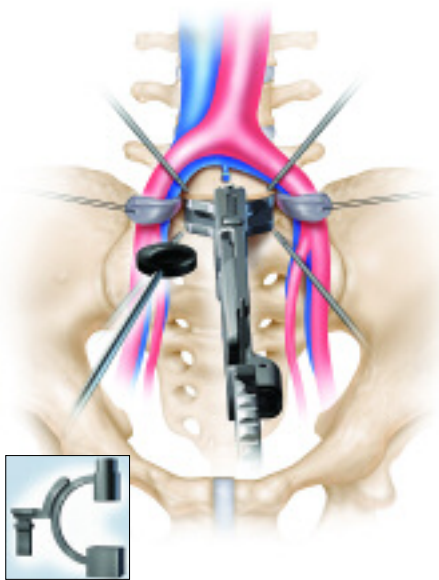
IV. IMPLANTATION



CORE TRIAL

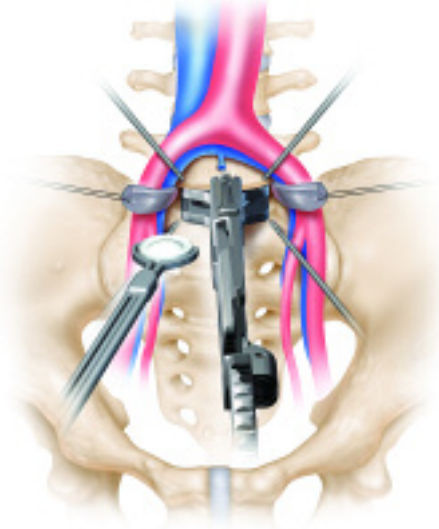
- With the Endplates now in place, open the disc space using the Spreading and Insertion Forceps.
- Sequentially distract the disc space using the Distraction Spacers and Module T-Handle corresponding to the core heights. **Care must be taken to avoid contact between the Spacer and the “polished” articulating surface of the Endplates. Therefore, a parallel orientation should be maintained between the shaft of the Spacer and the Spreading and Insertion Forceps.**
- Once the appropriate distraction is achieved, the size indicated on the Spacer can be used to select the appropriate Core Trial.





CORE TRIAL

- Confirm the appropriate height of Sliding Core by using the Core Trials placed between the Endplates.
- The surgeon may feel slight resistance as the Core Trial is passed through the rim of the articulating surfaces of the Endplates. Once the Core Trial is in position it articulates freely within the articulating surface of the Endplates. The Core Trial should never be impacted.
- If desired, the Core Trial can be inserted and the distraction force of the Spreading/Insertion Forceps released so that the endplates close around the Core Trial, demonstrating final position and height.
- A lateral X-ray can be taken to show the height and lordotic angle of the prosthesis.



CORE INSERTION

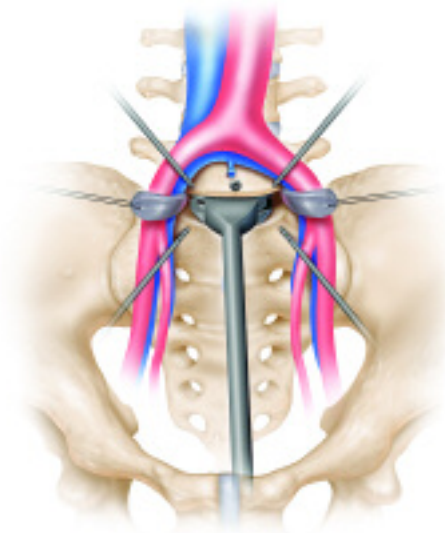
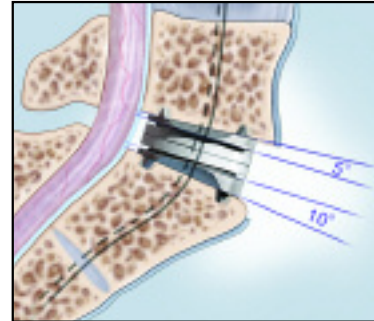
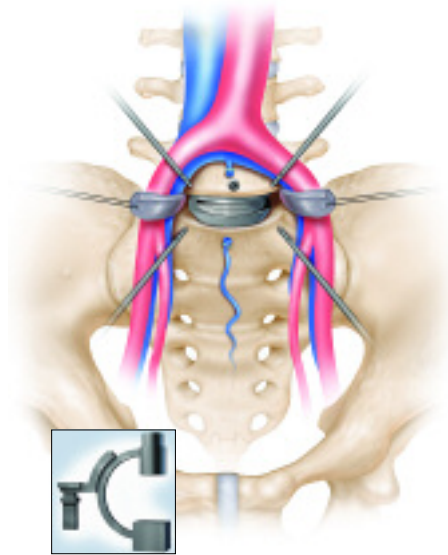
- Load the appropriate Core Insertion Tip into the Core Insertion Instrument.
- Insert the Sliding Core between the Endplates.
- Release the distraction on the Spreading and Insertion Forceps to cause the Endplates to close around and engage the Sliding Core.
- Release the Sliding Core by squeezing the handle of the Core Insertion Instrument.
- Remove the Core Insertion Instrument, then remove the Endplate Insertion Instrument.

CHARITÉ ARTIFICIAL DISC

IV. IMPLANTATION

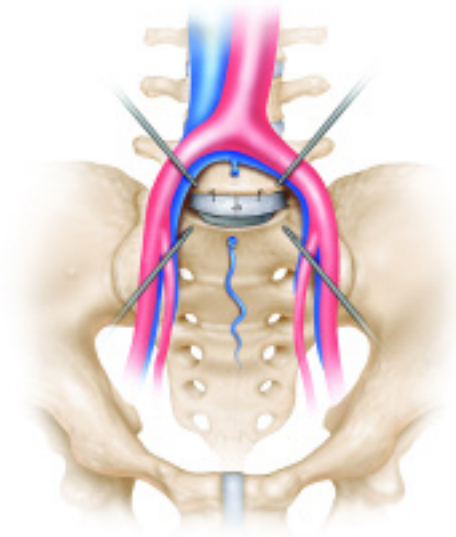
FINAL POSITIONING

- Verify the final position of the CHARITÉ Artificial Disc using fluoroscopy. It is imperative that the prosthesis is in the correct position in the AP and lateral planes.



- If necessary, the position of the prosthesis can be altered slightly using the appropriately sized Grooved Driver.
- The CHARITÉ Artificial Disc may be repositioned intra-operatively, in the event of a gross malposition. The entire prosthesis can be removed and reimplanted by carefully reversing the previous insertion steps.
- Once the final position has been confirmed, the Single Endplate Impactor may be used to manually engage the ventral fixation teeth of the Endplates into the vertebral body, thus providing initial fixation.

If necessary, a slap hammer can be added to aid in removal.



CLOSING

- ***Midline Marker must be removed prior to closing.***
- If desired, suture the annulus around the disc space. Remove the Retractor Pins in reverse order to that in which they were implanted with care being taken to protect the vasculature as they are removed.

Notes

CHARITÉ IDE SITES

CONSULTING SURGEONS

Hospital Name

Boston, MA Robert Banco, MD
Scott Tromanhauser, MD
Louis Jenis, MD

Hospital Name

New York, NY Fabien Bitan, MD

Hospital Name

Plano, TX Scott Blumenthal, MD
Richard Guyer, MD
Stephen Hochschuler, MD

Hospital Name

Lockport, NY Andrew Cappuccino, MD

Hospital Name

Columbia, MO Robert Gaines, MD
John Miles, MD

Hospital Name

Aventura, FL Rolando Garcia, MD

Hospital Name

Chicago, IL Fred Geisler, MD

Hospital Name

Louisville, KY Richard Holt, MD
Mohammed Madj, MD

Hospital Name

Baton Rouge, LA Jorge Isaza, MD

Hospital Name

Scottsdale, AZ James Maxwell, MD

Hospital Name

Towson, MD Paul McAfee, MD
Fedder, MD Ira

Hospital Name

Franklin, TN Michael McNamara, MD

Hospital Name

Columbus, OH Bradford Mullin, MD

Hospital Name

Los Angeles, CA John Regan, MD
Ted Goldstein, MD
Robert Bray, MD

Hospital Name

Golden, CO David Wong, MD
Courtney Brown, MD
* No longer active



I N D I C A T I O N S

The CHARITÉ Artificial Disc is indicated for spinal arthroplasty in skeletally mature patients with degenerative disc disease (DDD) at one level from L4-S1. DDD is defined as discogenic back pain with degeneration of the disc confirmed by patient history and radiographic studies. Patients receiving the CHARITÉ Artificial Disc should have had at least six months of conservative treatment prior to implantation of the CHARITÉ Artificial Disc; these treatments may include: discectomy, laminotomy/laminectomy (without accompanying facetectomy) or nucleolysis at the same level to be treated.

LIMITED WARRANTY AND DISCLAIMER: DePuy Spine products are sold with a limited warranty to the original purchaser against defects in workmanship and materials. Any other express or implied warranties, including warranties of merchantability or fitness, are hereby disclaimed.

WARNING: In the USA, this product has labeling limitations. See package insert for complete information.

CAUTION: USA Law restricts these devices to sale by or on the order of a physician.

DePuy Spine is a joint venture with Biedermann Motech GmbH.

DEPUY SPINE, CHARITÉ™ and CENTRELINE™ are all trademarks of DePuy Spine, Inc.

© 2004 DePuy Spine, Inc. All rights reserved.

To order, call DePuy Spine Customer Service (1-800-227-6633)



**Ingenuity. Integrity.
Infinite possibilities.™**

DePuy Spine, Inc.
325 Paramount Drive
Raynham, MA 02767